

# Stray Poodle Injured in a Hit and Run Accident

(photos may be seen at end of case)

Degloving injury, lateral aspect of left tarsus, starting at the hock and extending distally. Wound measuring 8cm x 3 cm, 25-50% circumference of the leg. A full-thickness wound with a moderate amount of necrotic tissue was present and bone substance evident.

The wound was dressed every day for three days, while exudate was heavy. *hyCURE®* interacted with the wound site, forming a gel when mixed with the wound's exudate. This provided a moist healing environment conducive to healing. Within three days, a newly formed granulation tissue bed had formed. As healing progressed, *hyCURE®* was applied every 2-3 days. Six days after injury, a betadine soak was used to debride a small amount of necrotic tissue over the point of the hock. At this point, a good bed of granulation tissue had formed. The wound size was 6 cm x 1 ½ cm.

In less than two weeks, skin contraction was present. Wound measured 5 ½ cm x ½ cm at the tarsus, 5 ½ cm x 1.2 cm at the hock. After 16 days of treatment with *hyCURE®*, there was increased skin contracture and good epithelialization of the wound bed. Wound measured 5 cm x .4 cm at the tarsus and 5 cm x .4 cm at the hock. Three days later, the wound was left to heal completely without a bandage.

In three weeks, the wound had completely healed at the tarsus with epithelialization still occurring at the hock (2 cm x .2 cm). At three weeks and four days post-treatment, the wound was completely healed.

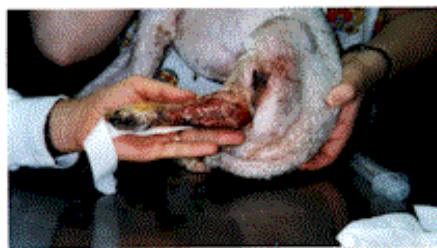Kimberly Kish, V.M.D.

Lisa Cawley, V.M.D.

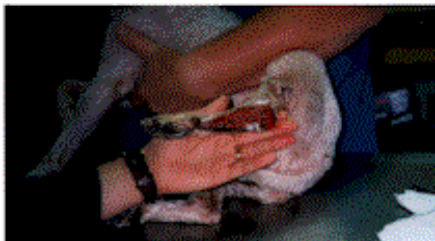Saucon Valley Animal Hospital

1979 Leithsville Road

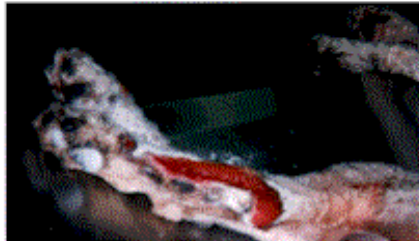
Hellertown, PA 18055



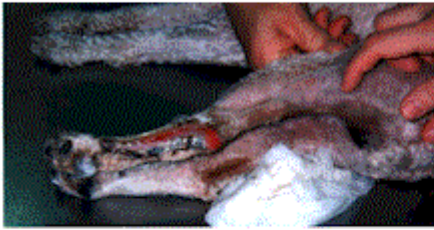
9/21/96 - Initial treatment with *hyCURE™*



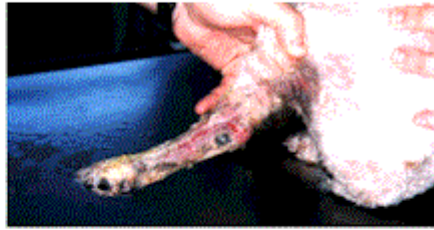9/24/96 - 3 days following initial treatment



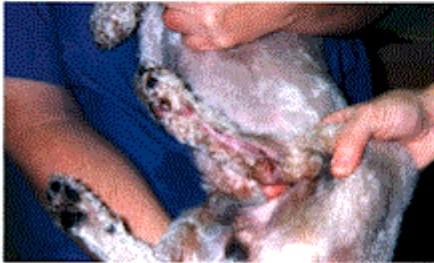9/27/96 - 6 days



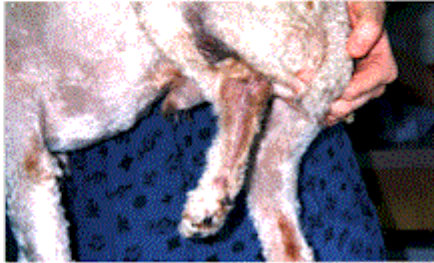
10/3/96 - 12 days



10/7/96 - 16 days



10/12/96 - 21 days



10/16/96 - 25 days - Wound Healed